



ELSEVIER

Contents lists available at [ScienceDirect](https://www.sciencedirect.com)

Trauma Case Reports

journal homepage: www.elsevier.com/locate/tcr

Case Report

A personalized approach to modify axillary crutches using 3D printing technology

Samar Ismaiel, Hamza A. Massadeh, Rasheed M. Fakhri*

MSF reconstructive surgical hospital, Jordan

ARTICLE INFO

Keywords:

Customization
Walking aid
3D printing
Patient-centered approach
Quality of life
Low resources
Case report

ABSTRACT

3D printers can produce specific medical objects that are tailored to the individual patient's needs, and if they are combined with a personalized orthopedic rehabilitation, it can result in improved functional outcomes. We present a 26-year-old male war victim with multiple injuries in his lower and upper limbs. The use of standard crutches was impossible, so we developed a customized 3D-printed crutch with a relative low cost. The gait and balance scores—as a part of the Tinetti score—improved immediately, and the patient's QUEST 2.0 questionnaire was high after 4 weeks of the crutches use, indicating high patient's satisfaction.

Introduction

With the advent of 3D technologies, many applications have been introduced in the medical arena with exponential growth in the past years. 3D printers can produce specific medical objects that are tailored to the individual patient's needs. When this technology is combined with a personalized approach to orthopedic rehabilitation, it can result in improved functional outcomes, patients' satisfaction, and patients' compliance [1,2]. This case report highlights how 3D printing technology was used to create a customized axillary crutch for a patient with specific deformities that made the use of traditional axillary crutches almost impossible. The report also elaborates on how the use of 3D printing technologies can produce a cost-effective solution in low-resource settings.

Case presentation

The patient was a war victim, a 26-year-old man who sustained a blast injury in Iraq in 2021, resulting in multiple injuries in his lower and upper limbs. The injuries included rupture of the left brachial plexus, fractures of the left shoulder, left radius, left-hand fingers, left lower femur, and upper tibia. After three major orthopedic surgeries in another hospital, the patient moved to complete his treatment at the Médecins Sans Frontières (MSF) reconstructive surgical hospital in Amman, Jordan, in January 2023 [3].

Upon arrival, an initial assessment was done (Table 1).

The patient had a femur corrective osteotomy with a bone distraction device at the MSF reconstructive surgery hospital. The post-operative order was for the patient to ambulate without bearing weight for 3 weeks, but this was not feasible using standardized walking aids. The poor functional status of the upper limb made the use of a traditional axillary crutch impossible due to the lack of stable vertical weight bearing on the axilla and the inability of the patient to have a proper hand grip to support his stability. The need for customization was a must, so we used our previous experience in 3D printing technology as part of the reconstructive surgical

* Corresponding author.

E-mail address: Rasheed.fakhri@paris.msf.org (R.M. Fakhri).

Table 1

Patient's presentation at admission to MSF's reconstructive surgery hospital.

Upper limb	Lower limb
<ul style="list-style-type: none"> • Atrophied left upper limb, internally rotated left shoulder with limited active and passive range of motion • Loss of active flexion in the left elbow associated with loss of pronation and supination (MRC 0) • Complete loss of function in the left wrist and hand (MRC 0) • Loss of sensation from the mid-left forearm to the hand 	<ul style="list-style-type: none"> • Malunion in the left femur with the external fixator in place • Locked left knee joint • Shortening of the left lower limb with a limb length discrepancy of 7 cm

MRC = Medical Research Council score, MSF = Médecins Sans Frontières.

project to print a better-fitting alternative walking aid that would help with ambulation and have optimum functionality [3].

Methods and modifications

A multidisciplinary team assessed the patient's situation and agreed on the following plan.

We used the 3D Scanner (Peel 3) to scan the patient's shoulder including the standardized axillary crutch. The desired printable upper mold was designed to hold the patient's left shoulder, fitting exactly to the anatomical shape of the shoulder area and to the upper end of the crutch. The final printed mold was fixed to the upper-axillary part of the crutch with screws (Fig. 1).

Using Fusion 360 software, a hook was designed to hold the patient's wrist and prevent swinging of the paralyzed limb, on the basis of the circumference of the left patient wrist. After 3D printing, the hook was press-fixed (without screws) on the standardized axillary crutch (Fig. 2). Both modifications (the mold and the hook) were printed on Ultimaker S5 3D printer using NGen flex filament. The process needed around 9 working days from scanning to the patient's first use. The total cost of the materials and printing was around 120 dollar and the cost of the HR was difficult to be analyzed due to their involvement in other activities in the project at the same period.

Results

Upon providing the patient with the customized 3D printed crutch, he was able to use it immediately (Fig. 3). The Tinetti Balance & Gait Assessment scores were measured few days before the scanning and then immediately after the first use by the patient. The Balance assessment score increased from 12 to 13 out of a total of 16, the Gait assessment score shifted from 0 to 7 out of a total of 12. Hereby, the total Tinetti score was raised from 12 to 20 out of 28 (from high fall risk to moderate fall risk, as scores lower than or equal to 18 are associated with high fall risk, and scores between 19 and 23 are associated with moderate fall risk).

We also used the QUEST 2.0 questionnaire to measure patient's satisfaction. This tool has been translated into several languages and has shown good validity and reliability, even in cross-cultural settings [4,5]. Since the questionnaire was not yet available in Arabic, a professional translator translated the score into Arabic. After providing consent and ensuring all parts were understood, the patient documented his answers on the form after 4 weeks from the first use of his custom crutches.

The total score was 58 out of 60, with the three most important satisfaction items being: easy to use, effectiveness, and service delivery.

Discussion and conclusion

In our case, we have seen an immediate, marked improvement in mobility after the introduction of the modified crutch. Moreover, the fall risk was immediately reduced, with the possibility of further improvement with additional specialized rehabilitation.

Remote follow-up visits and adaptations using these new technologies may further improve healthcare delivery and reduce costs. Technical experience can be gained with direct support at initial stages ending with independent team who can manage most of the cases efficiently. In case of a need for a remote project, the healthcare technician may use the scanner in their country (simple technique) and send the images to our hospital in Amman, where we can design the newly adapted mold, print it, and send it to the physiotherapist in their country. They can then train the patient to use the device with the new modification. This may represent an important step to assure continuity of care even in low-resources settings without a significant cost.

The collection of the patient's feedback using a satisfaction score as part of patient's centered approach may also show whether these new technologies improve the quality of life, healing, and rehabilitation for war-injured patients [6].

Declaration of competing interest

There was no direct funding source for this case report. All authors and participant are MSF's employees and this case management and reporting are parts of their daily activities.

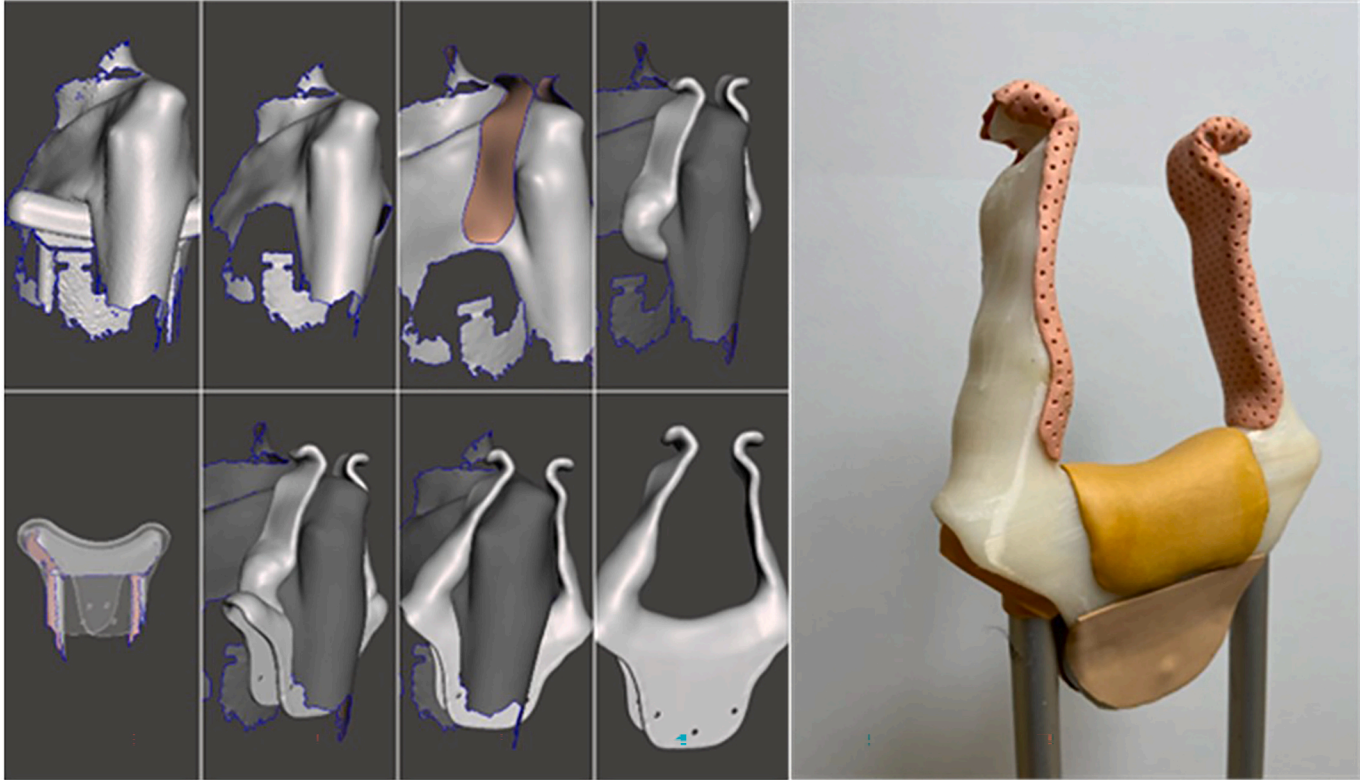


Fig. 1. Scan-based modification of the upper mold.

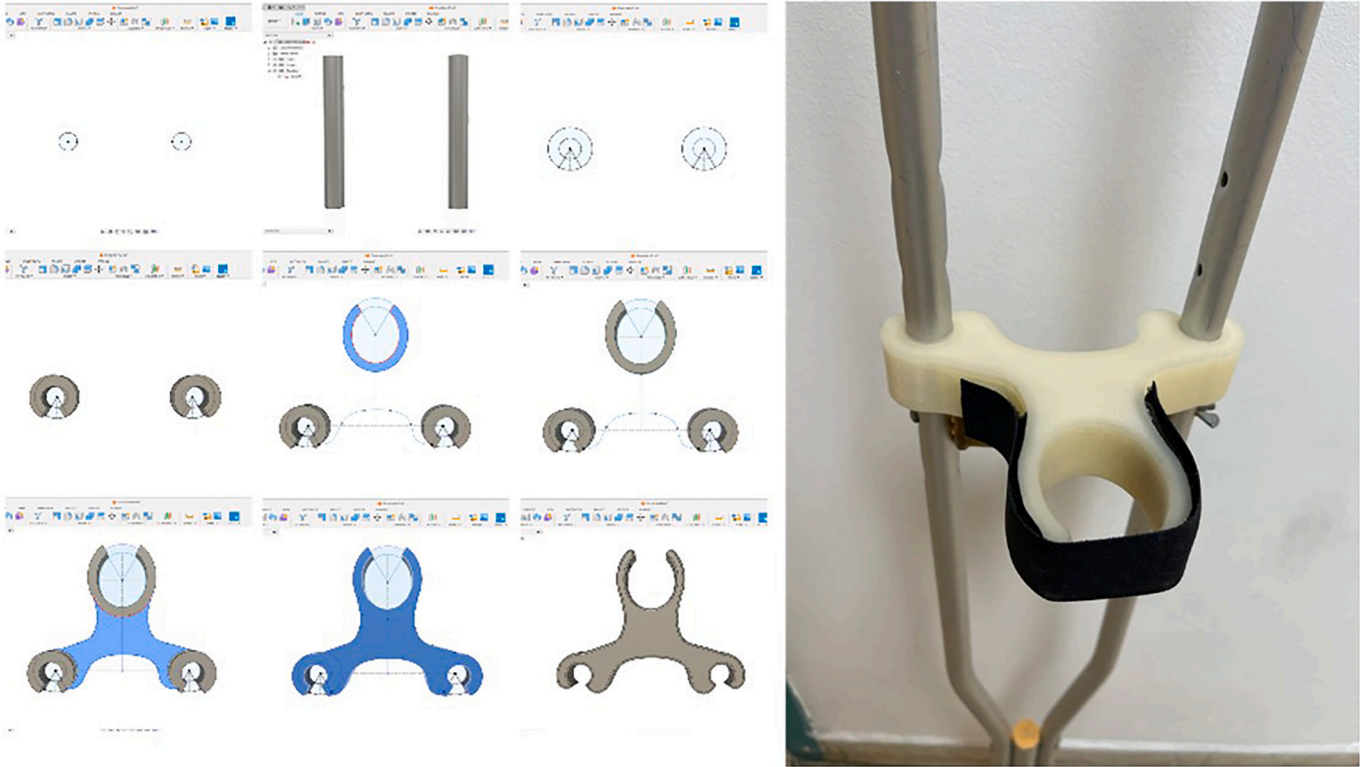


Fig. 2. Measurement-based modification of the lower hook.



Fig. 3. The patient using the crutch, full and partial weight bearing.

Acknowledgments

The authors would like to thank first the patient for accepting to share his information. Also, the authors like to thank all those who supported them in revising and editing the report especially Mrs. Janet Ousley, Dr. Evgenia Zelikova, Dr. Khalid Al Shaik.

References

- [1] R. Xu, Z. Wang, T. Ma, et al., Effect of 3D printing individualized ankle-foot orthosis on plantar biomechanics and pain in patients with plantar fasciitis: a randomized controlled trial, *Med. Sci. Monit.* 25 (2019) 1392–1400.
- [2] S.J. Kim, S.J. Kim, Y.H. Cha, et al., Effect of personalized wrist orthosis for wrist pain with three-dimensional scanning and printing technique: a preliminary, randomized, controlled, open-label study, *Prosthetics Orthot. Int.* 42 (2018) 636–643.
- [3] Médecins Sans Frontières, A Decade of Healing at MSF's Reconstructive Surgery Hospital. <https://www.msf.org/jordan-decade-healing-msf%E2%80%99s-reconstructive-surgery-hospital>. (Accessed 29 June 2023).
- [4] R.D. Wessels, et al., A Dutch version of QUEST (D-QUEST) applied as a routine follow-up within the service delivery process, in: I. Placiencia Porrero, E. Ballabio (Eds.), *Improving the Quality of Life for the European Citizen*, IOS Press, Amsterdam, 1998, pp. 420–424.
- [5] J. Guerreiro, E. Jiménez-Arberas, P. Porto Trillo, et al., Cross-cultural validation of quebec user satisfaction with assistive technology 2.0 for Spanish Population (QUEST-2.0 ES), *Int. J. Environ. Res. Public Health* 19 (15) (2022) 9349.
- [6] D. Yun, J. Choi, Person-centered rehabilitation care and outcomes: a systematic literature review, *Int. J. Nurs. Stud.* 93 (2019) 74–83.