

## PAEDIATRICS PSYCHIATRY

# A diagnostic challenge in an unresponsive refugee child improving with neurosurgery—a case report

George Makris<sup>1</sup>, Nefeli Papageorgiou<sup>2</sup>, Dimitrios Panagopoulos<sup>3</sup> and Katrin Glatz Brubakk<sup>4,5</sup>

<sup>1</sup>Medical Department, Médecins Sans Frontières-Operational Centre Brussels, Athens, Greece, <sup>2</sup>1st University Paediatric Clinic, Children's Hospital 'Agia Sofia', Athens, Greece, <sup>3</sup>Department of Neurosurgery, Children's Hospital 'Agia Sofia', Athens, Greece, <sup>4</sup>Medical Department, Médecins Sans Frontières-Operational Centre Brussels, Lesvos, Greece, <sup>5</sup>Department of Psychology, Norwegian University of Science and Technology, Trondheim, Norway

\*Correspondence address. Medecins Sans Frontieres, Operational Centre Brussels, Theophanous, 19-21, Athens, Greece. Tel: +0030 6978834669; E-mail: gkmakris@protonmail.com

## Abstract

An unresponsive paediatric patient may present a diagnostic challenge for health professionals, as rapid identification of the cause is needed to provide proper interventions. The following report details a challenging diagnosis of unresponsiveness in a refugee child. In the migratory context, observed unresponsiveness states are frequently attributed to psychologic factors, and overlapping psychiatric classifications (resignation syndrome, functional coma and catatonia) are common. Our patient fell into an unresponsive state for 6 months after witnessing a traumatic event. Diagnostic workup for multiple medical comorbidities led to surgical intervention for tethered cord syndrome. Shortly after that, the patient's responsiveness improved, putting to question her condition's underlying cause. This case highlights the need for a biopsychosocial approach in such cases, reflected in thorough clinical examination and diagnostic investigations. A multidisciplinary perspective and expertise proved crucial and may help in the rehabilitation of children in similar situations.

## INTRODUCTION

After the European Union-Turkey deal in 2016, asylum seekers are contained in the Greek islands in notoriously difficult living conditions [1]. Médecins Sans Frontières (MSF) provided Paediatric primary health care and mental health services in Moria, Europe's largest refugee camp. Approximately 40% of the population are children [2], who often have limited access to appropriate medical care due to movement restrictions and administrative constraints.

Factors such as previously undiagnosed, misdiagnosed, or untreated medical, neurodevelopmental and psychiatric problems, a history of past and ongoing traumatic events, as well as familial stress, complicate the provision of quality care in

these settings [3]. This report presents the challenges in diagnosing and managing a 9-year-old refugee girl presenting with progressive and pervasive unresponsiveness, multiple medical comorbidities, and a history of consecutive severe adverse life events.

Coma (and stupor to a lesser degree) denotes both lack of awareness and lack of response to external stimulation. As awareness is subjective, the latter criterion is more often used in clinical settings [4]. Unconsciousness and unresponsiveness can result from multiple underlying medical and psychiatric conditions, presenting as catatonia, functional coma and resignation syndrome. Resignation syndrome, a rare condition that has been described in asylum-seeking children in Sweden and Nauru, was one differential diagnosis explored in this case [5].

Received: November 28, 2020. Revised: January 25, 2021. Accepted: February 12, 2021

© The Author(s) 2021. Published by Oxford University Press. All rights reserved. For Permissions, please email: journals.permissions@oup.com

This is an Open Access article distributed under the terms of the Creative Commons Attribution Non-Commercial License (<http://creativecommons.org/licenses/by-nc/4.0/>), which permits non-commercial re-use, distribution, and reproduction in any medium, provided the original work is properly cited. For commercial re-use, please contact journals.permissions@oup.com

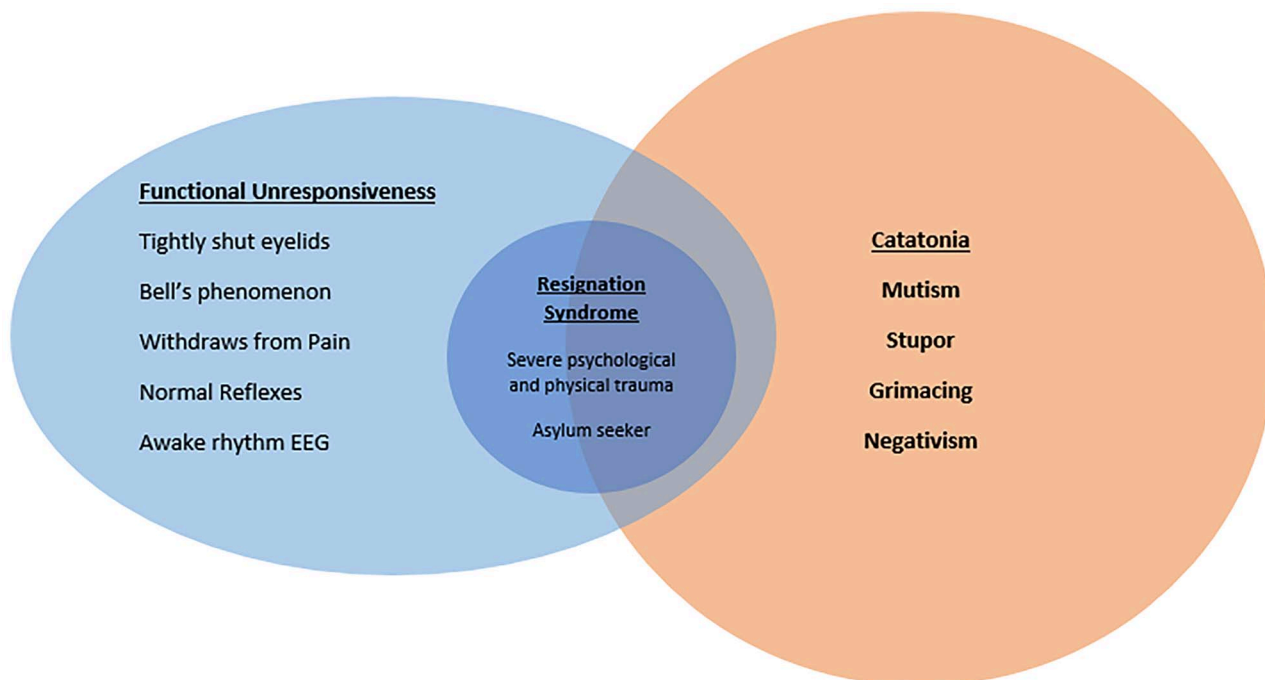


Figure 1: Venn diagram of risk factors and clinical signs pertinent to the differential diagnosis of chronic unresponsiveness in this case.

Nevertheless, the overlapping diagnostic classifications make a definitive diagnosis challenging and raise the question of the appropriate evidence-based treatment in such cases (Fig. 1).

## CASE REPORT

A 9-year-old Afghani female presented to the MSF clinic in August 2019 in a wheelchair due to chronic leg pain and difficulty walking, accompanied by her father. She had good eye contact, walked with support and responded to questions regarding herself.

Reportedly, in 2015 her left leg and lower back were severely injured in a bomb explosion in Afghanistan, during which she witnessed the death of her brother. Over the next 2 years, she underwent multiple operations on her femur in Pakistan and Turkey, where she remained separated from her family. Before the bomb explosion, her cognitive and social development was normal, and there was no reported history of psychiatric illness in the family.

While she was under the care of MSF, she witnessed a deadly stabbing attack in the camp on 26 August 2019, during which she was reported to be shaking, screaming and expressing her fear of dying. Following this, she became increasingly withdrawn, ceased speaking within a few days, shut her eyes and only swallowed when the father fed her. Weight loss of 1.2 kg is documented.

At the end of September 2019, due to her severe condition and in combination with the unstable conditions in the camp, the family was transferred to Athens. Shortly afterwards, she was admitted to a tertiary hospital. On admission, she had closed eyes, was mute and unresponsive to commands. Vital signs were normal. Deep tendon reflexes were normal, and Babinski's reflex was negative. She withdrew from painful stimuli.

The working diagnoses were resignation syndrome (grade 1) (see Box 1), which we consider a category of functional

stupor/coma, and catatonia secondary to possible organic causes. Resignation syndrome was considered due to her unresponsive state's manifestation following a violent incident, the previous traumatic history, and her refugee identity. Findings supporting resignation syndrome/functional coma included tightly shut eyelids, Bell's phenomenon when opening eyelids, withdrawal from pain and an awake rhythm EEG [4]. Catatonia was also a possibility due to pre-existing medical morbidities and the findings of stupor, mutism, negativism and grimacing [6].

A medical workup was initiated (Table 1), which revealed syringomyelia and tethered cord syndrome with bladder and bowel dysfunction, manifesting as urinary retention and constipation. During her hospitalization of 2 weeks, diagnostic examinations brought to light several conditions. These were: (i) right hip rigidity because of a four-time operated right femur; (ii) femur osteoporosis; (iii) vertebral synostosis of L3–L5 and sacral spine; (iv) scoliosis; (v) hypercalciuria and left renal pelvic lithiasis and (vi) recurrent urinary infections.

## THERAPEUTIC INTERVENTIONS

Psychosocial interventions included moving the family to improved living conditions and providing continuous psychological, social and legal support, which renewed the parents' hope for their asylum application approval. The family was informed in April 2020 that asylum in Greece was granted.

Initially, she was put on benzodiazepine treatment by a child psychiatrist, recommended for both catatonia and resignation syndrome. A low dose of risperidone was added for insomnia and night terrors. The benzodiazepines were considered ineffective and were gradually tapered, and treatment was initiated with fluoxetine.

No abnormalities were found on cardiologic evaluation. The father received support to feed and hydrate her to cover her

**Box 1:** Assessment scale for resignation syndrome\*

Symptom	Grade 1	Grade 2
Ability to communicate	Non-verbal response	No response at all
Ability to fulfil daily routines	If motivated/reminded	Not at all
Ability to move	Is able to walk with help	Lies down, not able to stand
		No facial expression
Basic survival skills	Is fed, chews or swallows on his/her own	Tube fed
Awareness about the world	Can hear or reacts to certain sounds. Can open eyes	Totally detached

\*Source: 'Asylum-seeking children with Resignation Syndrome—trauma, culture and the asylum process' (Asylsökande barn med uppgivenhetssyndrom-trauma kultur, asylprocess, SW, No. 49 ISBN 91-38-22 573-7), SOU Report [5].

**Table 1:** Diagnostic investigations conducted during the case and outcomes

Diagnostic investigations	Outcomes
Basic serum and urine studies	Unremarkable, except from urinary markers when UTI was present
Special serum studies-metabolic screening (ammonia, lactic acid, amino acid analysis, copper etc.),	Unremarkable
Calcium metabolism studies	Hypovitaminosis D, Hypercalciuria
Brain MRI (magnetic resonance imaging)	Unremarkable
EEG	Unremarkable, awake rhythm
Abdominal X-ray, Dimercaptosuccinic Acid scan and intravenous pyelography	Left renal pelvis kidney stone and urinary retention Minor functional renal impairment. Renal scars.
Lumbar spine MRI	Low position of the conus medullaris with a tight filum terminale, distended urinary bladder

daily nutritional needs. After nephrological evaluation, preventive treatment with hydrochlorothiazide and vitamin D was initiated for hypovitaminosis D and hypercalciuria.

To treat nephrolithiasis, an extracorporeal shock wave lithotripsy was scheduled after the insertion of a pig-tail catheter. Orthopaedic and neurosurgical evaluations revealed significant spinal findings consistent with tethered cord syndrome. The girl underwent an uncomplicated de-tethering operation through a central hemilaminectomy of the L4 and L5 vertebrae, under neurophysiological monitoring.

Her neurogenic bladder retention symptoms, which worsened before surgery, were managed with intermittent catheterizations and constipation with laxative treatment. The patient manifested two urinary tract infections (UTIs), both before implementing intermittent catheterizations, which were treated with antibiotics.

Unexpectedly, within a week after the surgery, she started to increase eye-opening, respond to environmental cues and engage in simple conversations with her family and others. She started individual sessions with a psychologist and began to write and draw. The patient reported no memory of the period of unresponsiveness (Fig. 2).

Multidisciplinary medical and psychological follow-up was strongly recommended.

## DISCUSSION

Our case exemplifies the importance of a biopsychosocial multidisciplinary approach to states of unresponsiveness in a vulnerable population. The diagnosis was not straightforward. In this case, the patient presented with a history of physical injuries and medical comorbidities. However, her unresponsiveness occurred

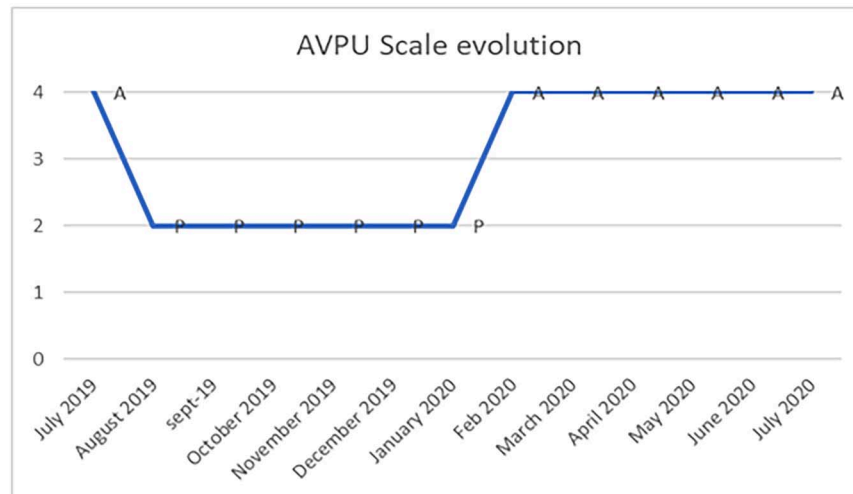
shortly after an event in the camp that led to re-traumatization. As part of the differential diagnosis, resignation syndrome was considered based on a clear link between the re-traumatization and the onset of the withdrawal symptoms [7]. Recovery from the syndrome is typically seen when the child is in a more stable situation with positive life prospects [7]. Catatonia, another diagnostic possibility, is increasingly recognised as a symptom cluster rather than a specific pathology and has medical causes in almost one in five children [8].

Unexpectedly, our patient's unresponsiveness resolved after a spinal surgical intervention. The diagnostic workup proved crucial to reveal the physical condition, even when numerous psychological and social factors could indicate a psychogenic cause of unresponsiveness. To our knowledge, this constellation of underlying conditions, clinical presentation and response to surgical treatment for tethered cord syndrome has not been described before for resignation syndrome or catatonic states.

Further research is needed to illuminate how medical comorbidities and/or the associated pain can interact with traumatic experiences to produce such states and the mechanisms through which physical treatments can aid recovery. We emphasize the importance of thorough medical investigations in refugees, asylum seekers and migrants, as underlying physical conditions often remain undiagnosed and untreated. Medical treatments and psychosocial interventions need to occur hand in hand for the refugee and migrant populations whose lives have been complicated by difficult and traumatic events.

## CONFLICT OF INTEREST

No conflicts of interest declared.



Events/interventions: Aug. '19: Traumatic event in camp, Sept. '19: Evacuation from camp and lawyer appointed, Oct. '19: Psychological support to family started, Feb. '20: Neurosurgical operation, Apr. '20: Asylum in Greece granted

Figure 2: Evolution on the AVPU (Alert/Responsive to verbal stimuli/Responsive to pain/Unresponsive) scale over time.

## FUNDING

There is no specific funding for this study.

## ETHICAL APPROVAL

For this study, we have obtained the written informed consent from the patient's guardian and conducted a risk-benefit analysis of this publication.

## GUARANTOR

George Makris is the guarantor of this case report.

## ACKNOWLEDGEMENTS

We want to thank the patient and the family for their trust. In addition, we want to thank all MSF staff in Lesvos and Athens, who participated in the effort to provide the best possible care for our patient, as well as the professionals from NGO Babel, RSA and Praksis for their valuable assistance in this case. 'Agia Sofia' Children's Hospital medical staff also provided indispensable medical services for this patient. Finally yet importantly, we want to thank sincerely Temmy Sunyoto and Marlene Goodfriend for their continuous guidance and support.

## REFERENCES

- Mijatović D. Report of the Commissioner for Human Rights of the Council of Europe following her visit in Greece, Strasbourg: Commissioner for Human Rights, November 8, 2018.
- UNHCR. Aegean Islands Monthly Snapshot, Greece: UNHCR, November 2019.
- Fazel M, Reed RV, Panter-Brick C, Stein A. Mental health of displaced and refugee children resettled in high-income countries: risk and protective factors. *Lancet* 2012;379:266–82. doi: 10.1016/S0140-6736(11)60051-2.
- Ludwig, L., L. McWhirter, S. Williams, C. Derry, and J. Stone. "Functional Coma." In *Handbook of Clinical Neurology*, 139:313–327. Elsevier, 2016. doi:10.1016/B978-0-12-801772-2.00028-X.
- Sverige, Nationella samordnaren för barn i asylprocessen med uppgivenhetssymtom. *Asylsökande barn med uppgivenhetssymtom: trauma, kultur, asylprocess: rapport*. Stockholm: Fritze, 2006.
- American Psychiatric Association. *Diagnostic and Statistical Manual of Mental Disorders: DSM-5*, 5th edn. Washington, DC: American Psychiatric Publishing, 2013.
- Knorrig A-L v, Hultcrantz E. Asylum-seeking children with resignation syndrome: catatonia or traumatic withdrawal syndrome? *Eur Child Adolesc Psychiatry* 2020;29:1103–9. doi: 10.1007/s00787-019-01427-0.
- Hauptman AJ, Benjamin S. The differential diagnosis and treatment of catatonia in children and adolescents. *Harv Rev Psychiatry* 2016;24:379–95. doi: 10.1097/HRP.0000000000000114.