



## **False-positive Xpert(®) MTB/RIF assays in previously treated patients: need for caution in interpreting results.**

Authors	Boyles, T H; Hughes, J; Cox, V; Burton, R; Meintjes, G; Mendelson, M
Citation	False-positive Xpert(®) MTB/RIF assays in previously treated patients: need for caution in interpreting results. 2014, 18 (7):876-8 Int. J. Tuberc. Lung Dis.
DOI	<a href="https://doi.org/10.5588/ijtld.13.0853">10.5588/ijtld.13.0853</a>
Journal	International Journal of Tuberculosis and Lung Disease
Rights	Archived with thanks to The International Journal of Tuberculosis and Lung Disease : the official journal of the International Union against Tuberculosis and Lung Disease
Download date	03/10/2021 17:23:18
Link to Item	<a href="http://hdl.handle.net/10144/322672">http://hdl.handle.net/10144/322672</a>

## False-positive Xpert® MTB/RIF assays in previously treated patients: need for caution in interpreting results

T. H. Boyles,\* J. Hughes,<sup>†</sup> V. Cox,<sup>†</sup> R. Burton,<sup>‡</sup> G. Meintjes,<sup>§</sup> M. Mendelson\*

\*Division of Infectious Diseases and HIV Medicine, Department of Medicine, Groote Schuur Hospital, University of Cape Town, Cape Town, <sup>†</sup>Médecins Sans Frontières, Khayelitsha, Cape Town, <sup>‡</sup>Khayelitsha District Hospital, Khayelitsha, Cape Town, <sup>§</sup>Institute of Infectious Disease and Molecular Medicine, University of Cape Town, Cape Town, South Africa

### SUMMARY

Xpert® MTB/RIF is the initial diagnostic test of choice for tuberculosis (TB). It is not known if false-positive results are more common in previously treated patients. We report four patients with successful treatment for TB up to 5 years previously who presented with respiratory tract infection and were Xpert-positive, but had negative TB cultures and clinical improvement without anti-

tuberculosis treatment. We hypothesise that the Xpert results were false-positive due to the presence of dead *Mycobacterium tuberculosis* bacilli in lungs and sputum. Further work is required to determine the specificity of Xpert in previously treated patients.

**KEY WORDS:** tuberculosis; diagnostic test; specificity

THE WORLD HEALTH ORGANIZATION (WHO) has endorsed the roll-out of Xpert® MTB/RIF (Cepheid, Sunnyvale, CA, USA) as the initial diagnostic test in persons suspected of having multidrug-resistant tuberculosis (MDR-TB) or human immunodeficiency virus associated TB.<sup>1</sup> A recent systematic review and meta-analysis including 15 studies with 7517 participants found a pooled sensitivity of 88% (95% credibility interval [CrI] 83–92) and pooled specificity of 98% (95%CrI 97–99) if microscopy was replaced by Xpert as the initial diagnostic test.<sup>2</sup> It has not been reported whether patients with false-positive Xpert results are more likely to have had a previous episode of TB; however, Xpert does not distinguish dead from living bacilli. It is theoretically possible for the test to be positive in patients who do not have active disease but still have dead *Mycobacterium tuberculosis* bacilli in their lungs and sputum from a previously treated episode of active TB. In such cases, sputum culture would be negative and the patient would not require anti-tuberculosis treatment. This possibility is supported by a recent study showing that after 6 months of standard treatment, 27% of patients remain Xpert-positive, although only 4% are positive using liquid culture.<sup>3</sup> Conversion of Xpert to negative is therefore not a suitable marker of treatment success, and positivity may persist despite successful treatment.

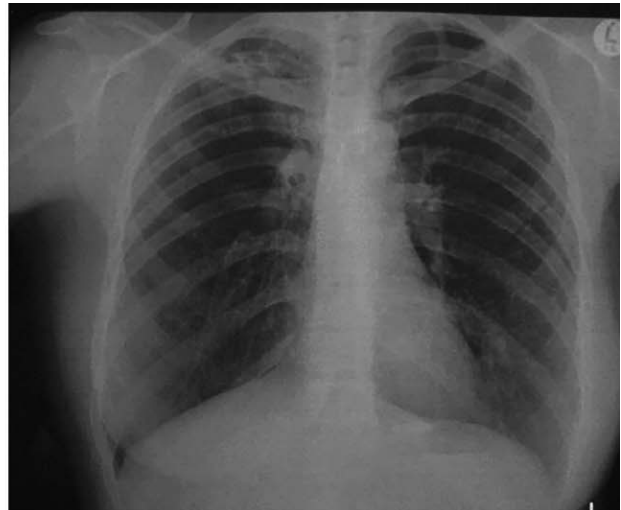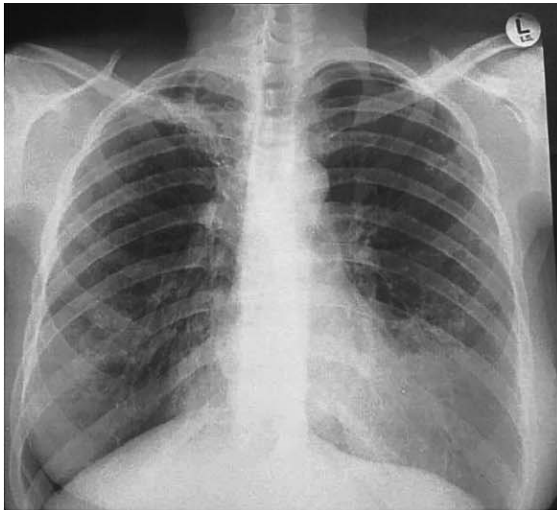
We report four patients with a history of successfully treated TB who presented with lower respiratory tract infections, positive Xpert results, negative liquid TB cultures and clinical improvement without anti-tuberculosis treatment, suggesting that the Xpert result was falsely positive.

### CASE REPORT

Patient 1 was diagnosed with MDR-TB based on sputum culture 7 years previously. She initiated a standardised five-drug MDR-TB treatment regimen and became culture-negative after 135 days. She completed 18 months of treatment and achieved cure. She later presented with a 1-week history of shortness of breath and a productive cough. Chest X-ray showed fibrotic changes with nodules at the hila and right upper zone, and a diffuse infiltrate in lingula of the left lower lobe (Figure). She was treated with oral amoxicillin while awaiting sputum results. The first sputum sample was Xpert-positive with rifampicin (RMP) resistance. She remained clinically stable, and as her symptoms had improved, anti-tuberculosis treatment was delayed to await the culture results. Two sputum samples obtained at this time were both culture-negative after 6 weeks' incubation. On clinical re-assessment at this point, she was asymptomatic and the lingula infiltrate on the CXR had largely resolved (Figure). Repeat sputum

Correspondence to: Tom H. Boyles, Division of Infectious Diseases and HIV Medicine, Department of Medicine, Groote Schuur Hospital, Observatory, Cape Town, South Africa. Tel: (+27) 791 081 876. Fax: (+27) 865 793 279. e-mail: [tomboyles@yahoo.com](mailto:tomboyles@yahoo.com)

Article submitted 26 November 2013. Final version accepted 9 March 2014.



**Figure** Chest X-ray during respiratory tract infection (left) and following resolution of symptoms (right) for Case 1.

sampling was again Xpert-positive with RMP resistance, but TB liquid culture was negative. The patient did not receive anti-tuberculosis treatment, and she remained clinically well 5 months after initial presentation.

Three other cases fulfilled the case definition of having a previous episode of TB, positive Xpert result, negative mycobacterial culture and clinical improvement without anti-tuberculosis treatment (Table).

## DISCUSSION

We present four patients with a history of treated TB who had completed treatment up to 5 years previously. All were Xpert-positive during an intercurrent respiratory tract infection with negative mycobacterial cultures of sputum and clinical improvement without anti-tuberculosis treatment. We hypothesise that these positive Xpert results indicate the presence of mycobacterial DNA from dead bacilli persisting in lung tissue expectorated at the time of an intercurrent chest infection, and therefore falsely positive with respect to the diagnosis of active TB.

Treatment algorithms suggest that all patients with positive Xpert results should immediately start anti-tuberculosis treatment. Only a minority who are seen by specialists are likely to have treatment withheld when the clinical suspicion of active TB disease is low. As such, it is difficult to estimate the scale of the problem, although these cases were collected within a single city over the course of 4 months, suggesting that it might be fairly common. It will be important to estimate the true incidence of false-positive Xpert results in treatment-experienced patients to avoid unnecessary anti-tuberculosis treatment with potential side effects. If this proves to be a common

occurrence, it will be necessary to change the treatment algorithms.

These cases suggest that the specificity of Xpert in patients with previous TB may be lower than previously thought. Despite a pooled specificity of 98% (95%CrI 97–99) in a recent Xpert diagnostic accuracy study,<sup>2</sup> there is reason to doubt this figure. The two largest studies that contributed 5250 of the 7517 patients in the review used an imprecise reference standard to diagnose TB.<sup>4,5</sup> Both of these studies described a group of patients classified as having clinical TB with negative sputum culture. The proportion of patients in this group with positive Xpert results was lower than in those with positive sputum culture. In both trials, this group was excluded from the primary analysis and therefore from the review. The justification for this exclusion is unclear, but is not appropriate in a study of diagnostic accuracy. It is possible that some patients with positive Xpert results and negative cultures were retreatment cases with false-positive results. Excluding such cases from the analyses and from the systematic review would have the effect of increasing the reported specificity of the Xpert assay.

There is an urgent need to re-examine data from all previous diagnostic trials to include patients with clinical TB, some of whom were Xpert-positive and TB culture-negative, and to determine the specificity specifically in retreatment cases when such analyses are conducted. Further prospective studies may then be necessary to quantify the scale of the problem, and define in what proportion of patients Xpert remains positive after successful anti-tuberculosis treatment and define the duration of this phenomenon and what factors predispose to this. Whether patients previously treated for TB may convert from Xpert-negative to false-positive at the time of a bacterial

**Table** Details of four patients presenting after previous successful anti-tuberculosis treatment with respiratory tract infection and positive Xpert but negative TB cultures and clinical improvement without anti-tuberculosis treatment

Patient	Initial TB regimen, outcome*	Time from end of treatment to current presentation	Clinical presentation and course	CXR changes	Xpert MTB/RIF ±	Negative cultures n	Period since Xpert result	Current clinical status
1	MDR-TB, cured	5 years and 6 months	1 week of dry cough and malaise, symptoms resolved after antibiotic treatment	Left lingula lobar pneumonia that resolved after antibiotic treatment	2/0	3	5 months	Well
2	3RHZE/5RHE, cured	2 months	3 presentations with productive cough and fever resolved after antibiotic treatment†	Widespread bronchiectatic changes, little improvement after antibiotic treatment	2/1	1	3 months	Chronic cough
3	2RHZE/4RH, treatment completed	1 month	1 week of productive cough, shortness of breath and fever resolved after antibiotics	Widespread bronchiectasis and aspergilloma	1/0	2	1 month	Well
4	2RHZE/7RH, treatment completed	5 months	1 week of productive cough resolved after broad spectrum antibiotics	Left lower zone infiltrate on CXR; marked improvement after antibiotic treatment	1/1	4	3 months	Well

\* Numbers before the letters indicate the duration in months of the phase of treatment.

† Patient received 1 month of standard anti-tuberculosis treatment with no clinical improvement.

TB = tuberculosis; CXR = chest radiography; MDR-TB = multidrug-resistant TB; R = rifampicin; H = isoniazid; Z = pyrazinamide; EMB = ethambutol.

chest infection (as in these four cases) due to lung inflammation also needs to be investigated.

*Conflict of interest:* none declared.

## References

- 1 World Health Organization. Automated real-time nucleic acid amplification technology for rapid and simultaneous detection of tuberculosis and rifampicin resistance: Xpert MTB/RIF System. WHO/HTM/TB/2011.4. Geneva, Switzerland: WHO, 2011. [http://whqlibdoc.who.int/publications/2011/9789241501545\\_eng.pdf](http://whqlibdoc.who.int/publications/2011/9789241501545_eng.pdf). Accessed April 2014.
- 2 Steingart K, Sohn H, Schiller I, et al. Xpert® MTB/RIF assay for pulmonary tuberculosis and rifampicin resistance in adults. *Cochrane Database Syst Rev* 2013; 1: CD009593.
- 3 Friedrich S O, Rachow A, Saathoff E, et al. Assessment of the sensitivity and specificity of Xpert MTB/RIF assay as an early sputum biomarker of response to tuberculosis treatment. *Lancet Respir Med* 2013; 1: 462–470.
- 4 Boehme C C, Nabeta P, Hillemann D, et al. Rapid molecular detection of tuberculosis and rifampin resistance. *N Engl J Med* 2010; 363: 1005–1015.
- 5 Boehme C C, Nicol M P, Nabeta P, et al. Feasibility, diagnostic accuracy, and effectiveness of decentralised use of the Xpert MTB/RIF test for diagnosis of tuberculosis and multidrug resistance: a multicentre implementation study. *Lancet* 2011; 377: 1495–1505.

---

RESUME

Le test Xpert® MTB/RIF est l'examen idéal pour le diagnostic initial de la tuberculose. On ne sait pas si les faux positifs sont plus fréquents chez les patients déjà traités. Nous présentons quatre patients dont le traitement anti-tuberculeux a réussi jusqu'à 5 ans auparavant et qui se présentent avec une infection respiratoire et un test Xpert positif mais une culture

négative et une amélioration clinique sans traitement anti-tuberculeux. Nous émettons l'hypothèse que les résultats du Xpert sont des faux positifs dus à la présence de bacilles de *Mycobacterium tuberculosis* morts dans les poumons et les crachats. Un travail supplémentaire est nécessaire afin de déterminer la spécificité du Xpert chez des patients préalablement traités.

---

RESUMEN

La prueba Xpert® MTB/RIF es el método inicial de elección en el diagnóstico de la tuberculosis (TB). Se desconoce si los resultados positivos falsos son más frecuentes en los pacientes con antecedente de tratamiento. En el presente artículo se comunican cuatro casos de pacientes con antecedente de tratamiento eficaz de la TB hasta 5 años antes de acudir por infección respiratoria y presentar un

resultado positivo a la prueba Xpert, con cultivo negativo y sin respuesta clínica al tratamiento antituberculoso. Se plantea la hipótesis de que los resultados de la prueba fueron positivos falsos, debido a la presencia de bacilos de *Mycobacterium tuberculosis* no viables en los pulmones y el esputo. Se precisan nuevos trabajos que determinen la especificidad del método Xpert en los pacientes previamente tratados.

---