



More Challenges From Ebola: Infection of the Central Nervous System

Authors	Wong, G; Qiu, X; Bi, Y; Formenty, P; Sprecher, A; Jacobs, M; Gao, GF; Kobinger, G
Citation	More Challenges From Ebola: Infection of the Central Nervous System 2016, 214 (suppl 3):S294 Journal of Infectious Diseases
DOI	10.1093/infdis/jiw257
Publisher	Oxford University Press
Journal	Journal of Infectious Diseases
Rights	Archived with thanks to Journal of Infectious Diseases
Download date	03/10/2021 17:55:11
Link to Item	http://hdl.handle.net/10144/618793

More Challenges From Ebola: Infection of the Central Nervous System

Gary Wong,^{1,4,5} Xiangguo Qiu,^{4,5,a} Yuhai Bi,^{1,3} Pierre Formenty,⁷ Armand Sprecher,⁸ Michael Jacobs,⁹ George F. Gao,^{1,2,3} and Gary Kobinger^{4,5,6,10,a}

¹CAS Key Laboratory of Pathogenic Microbiology and Immunology, Institute of Microbiology, Chinese Academy of Sciences, ²Office of the Director General, Chinese Center for Disease Control and Prevention, Beijing, and ³Shenzhen Key Laboratory of Pathogen and Immunity, Shenzhen Third People's Hospital, China; ⁴Special Pathogens Program, National Microbiology Laboratory, Public Health Agency of Canada, ⁵Department of Medical Microbiology, and ⁶Department of Immunology, University of Manitoba, Winnipeg, Canada; ⁷Department of Pandemic and Epidemic Diseases, World Health Organization, Geneva, Switzerland; ⁸Médecins Sans Frontières, Operational Center of Brussels, Belgium; ⁹Department of Infection, Royal Free London NHS Foundation Trust, London, United Kingdom; and ¹⁰Department of Pathology and Laboratory Medicine, University of Pennsylvania School of Medicine, Philadelphia

Cases of relapsed Ebola virus disease involving symptoms in the central nervous system are reminiscent of our past observations with some nonhuman primates (NHPs) that survived acute Ebola virus infection. We document our findings in detail here and suggest that this phenomenon can be further investigated in NHPs.

Keywords. Ebola virus; central nervous system; nonhuman primates; relapse; outbreak.

A disease outbreak due to Ebola virus (EBOV) has caused >28 000 infections and 11 000 deaths since it was first reported in March 2014, with Guinea, Sierra Leone, and Liberia the hardest-hit countries [1]. Experimental therapies, including drug molecules and antibody-based products such as convalescent plasma and cocktails of monoclonal antibodies [2], have been used in limited EBOV-infected patients, on compassionate grounds. This may have positively influenced the rapid clinical evaluation of several experimental treatments in various clinical trials and led to optimism that a cure for EBOV disease could be identified and approved for use in humans. On 8 October 2015 it was reported that a nurse from the United Kingdom, who had survived EBOV infection in January 2015, experience relapse of EBOV disease (EVD) despite no further exposure to the virus [3]. The nurse's health reportedly declined to critical condition before improving, with central nervous system (CNS) symptoms and the presence of EBOV in her blood and spinal fluid [4]. Sixty-five close contacts were monitored as a result. This unfortunate development highlights how little is still currently known about EBOV clearance in survivors and the possible associated risks of EVD recurrence, even months after complete clinical recovery.

Histopathological studies have shown that EBOV initially targets the liver and spleen of infected patients. The virus replicates and disseminates to other organs via the lymphatic and vascular systems during advanced disease, including the lungs, kidney, gonads, endocardium, and the gastrointestinal tract [5]. This EBOV dissemination plays a considerable role in virus shedding from the oral, nasal, and rectal routes of patients, as well as the multiorgan

failure associated with fatal EVD cases. Among the too few who survive EVD, recovery is often prolonged. Infectious EBOV has been isolated from the breast milk and semen of convalescent survivors when tested approximately 3 months after recovery [6] and is still detectable by quantitative reverse transcription–polymerase chain reaction (qRT-PCR) in semen samples 9 months after infection [7], but it is not known whether the virus is still infectious at this stage. EBOV has also been isolated from the ocular fluids of a convalescent patient 9 weeks after virus clearance from blood [8]. One documented case from Monrovia during the outbreak in Western Africa occurred in a 9-year-old boy who had an ordinary course of EVD followed by a clinical recovery, including the resolution of fever and gastrointestinal symptoms. Two days after his discharge, he was noted to have a return of fever, with meningeal signs, and results of repeat PCR for detection of EBOV were positive [9]. It was thought that a false-negative PCR result led to his erroneous discharge, but another plausible explanation is a relapse to EVD, especially since the boy had recovered clinically. A 30 year-old patient in Sierra Leone also had delayed onset of neurological symptoms, with a 2–3 day window of improvement between acute EBOV illness and relapse to disease [10]. While this means that some patients are hypothetically infectious to others during convalescence, and considering that at least 1 case of sexual transmission from a survivor has been documented [11], the recurrence of EVD after recovery has been only suspected in rare cases of reemergence of EBOV and/or sudden death of survivors. Furthermore, the quick relapse of EVD in some patients suggests that recently discharged patients should be closely followed up and monitored, which may be difficult to achieve during the midst of an outbreak but should be completed if possible.

These developments reminded us of a treated rhesus macaque in a past study that experienced EVD relapse despite apparently surviving and recovering from the infection. The nonhuman primate (NHP) was treated with 1×10^9 plaque-forming units per kg of an adenovirus-vectored adjuvant 1 day after infection,

^aX. Q. and G. K. contributed equally to this work.

Correspondence: G. Kobinger, Special Pathogens Program, National Microbiology Laboratory, Public Health Agency of Canada, 1015 Arlington Street, Winnipeg, MB, Canada (gary.kobinger@crchudequebec.ulaval.ca)

The Journal of Infectious Diseases® 2016;214(S3):S294–6
 © Crown copyright 2016. DOI: 10.1093/infdis/jiw257

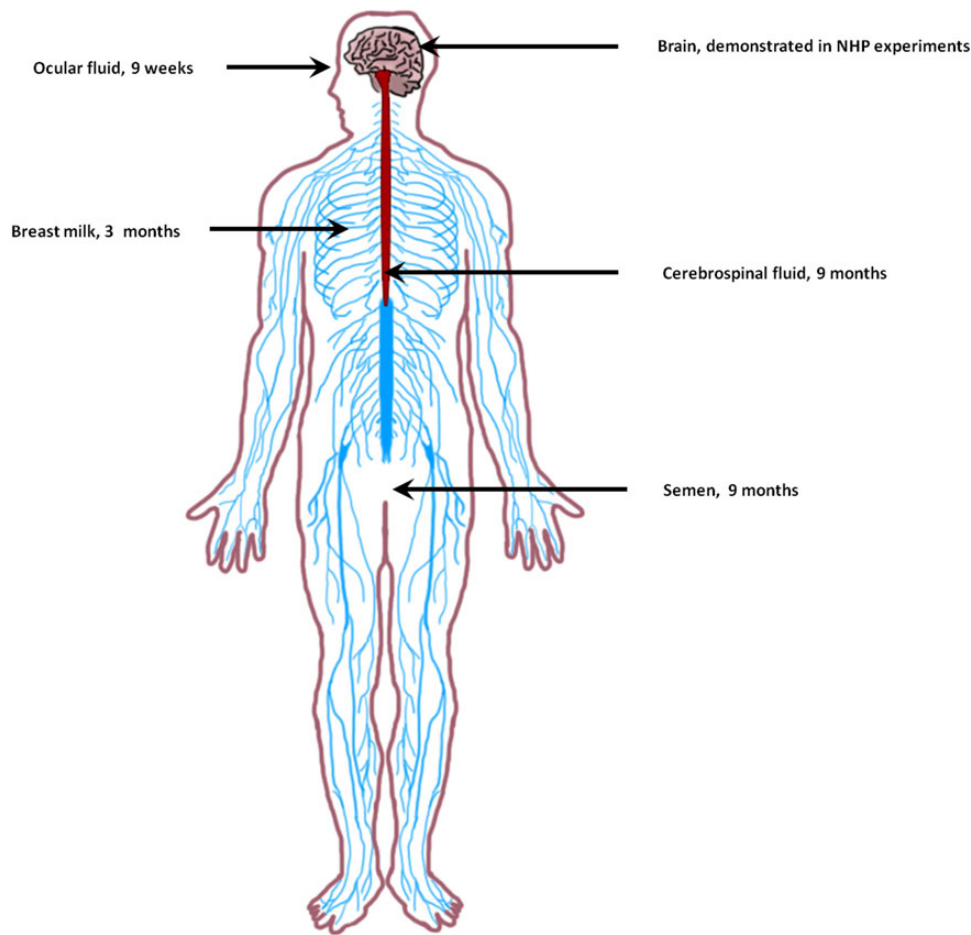


Figure 1. Locations where Ebola virus (EBOV) can hide within the human and nonhuman primate (NHP) central nervous and reproductive systems. Weeks/months listed represent the time elapsed between recovery from EBOV infection and when the virus was subsequently redetected (by virus isolation or quantitative reverse transcription–polymerase chain reaction in the patient without further exposure to EBOV).

followed by 3 doses of 50 mg/kg ZMAb (a cocktail of 3 monoclonal antibodies—1H3, 2G4, and 4G7—that preceded ZMapp) 3, 6, and 9 days after infection. A viremia level of approximately 10^5 50% tissue culture infective doses was detected 3 days after infection, but it decreased with treatment and was undetectable 16 days after infection. The clinical score had also dropped to 0 by 17 days after infection, suggesting that this animal had fully recovered from disease [12]. Clinical examination 16 days after infection still showed increased alanine aminotransferase and depressed platelet concentrations, which are indicative of liver damage and coagulopathy, respectively, and are common in NHPs recovering from EBOV infection [12]. High concentrations of immunoglobulin M and immunoglobulin G (1600 and 4000 end point dilutions, respectively) 16 days after infection indicate that this animal had developed robust humoral responses against the infection [12]. However, 22 days after infection, this animal again showed observable clinical symptoms, including holding its head with both front paws (a sign of headache) and partial paralysis, which is indicative of CNS involvement. The condition

of the animal deteriorated rapidly, with unilateral paralysis, and it had to be euthanized 24 days after infection as a result [12]. Analysis of a cerebrospinal fluid (CSF) specimen, harvested postmortem, showed that the sample was positive for EBOV (5.81×10^6 copy numbers of viral genome per mL). At that time, the level of virus detected in the blood was 5.93×10^7 copy numbers of viral genome per mL. These results suggest that EBOV can linger and even likely replicate within the CNS (Figure 1) and later in the blood.

Another NHP treated with small interfering RNA designed against the EBOV VP24, VP35, and L genes showed mild clinical disease 8–15 days after infection, along with a mild petechial rash, but it recovered and appeared perfectly normal clinically 15–20 days after infection. However, 21 days after infection the animal developed CNS manifestations leading to paralysis of the hind limbs and had to be euthanized 22 days after infection as a result. EBOV was detected by qRT-PCR in a CSF specimen from this animal (unpublished data from Dr Geisbert). CNS manifestations have also been observed in other convalescent

NHPs that were treated shortly after lethal challenge with adenovirus-based vaccines, recombinant human interferon β 1a, as well as rhAPC and NAPc2, 2 anticoagulant molecules previously investigated as a treatment against EVD ([13] and unpublished data from Drs Geisbert and Kobinger).

While these observations were anecdotal mainly because they were rare unexpected outcomes and consequently not always documented in detail, EBOV was detected in the CSF and blood of the animals tested. The concept that EBOV can reach the CNS is further supported by the pathologic findings from a past study, in which treatment of some NHPs with recombinant interferon resulted in observable tropism and infection of EBOV in the brain and eyes of the animals, possibly owing to the extended time course of the disease [13]. One important question is whether experimental therapies had blunted the immune response in the peripheral blood of the host, allowing unchecked virus replication in the immunologically protected sites, which in turn would favor renewed EBOV replication. Considering the very low incidence of CNS involvement in vaccinated or treated animals infected with EBOV (around 5 of approximately 400 NHPs), it is possible that this phenomenon is being observed only because the host would have otherwise died from the infection in the absence of the vaccine or treatment. However, animal models have several limitations, and a better understanding of this phenomenon in the context of natural recovery in humans will be important to acquire.

The frequency of EBOV infection of the CNS in animals or humans is unknown. Because of the large number of survivors from EBOV infection from Western Africa, one can suspect that the United Kingdom nurse is not the first or the only recovering patient to experience EVD relapse with CNS-related symptoms. She is however the first documented case of EVD reoccurrence with CNS involvement, bringing to light this phenomenon. Further attention to CNS targeting by filoviruses will be of importance to better understand the consequences and transmission risks associated with the reoccurrence of disease in survivors. The ability of the virus to hide in the CNS also offers an interesting hypothesis that could explain why the reservoir species for EBOV has been so difficult to identify with certitude. These developments have further implications for preclinical testing of medical countermeasures against EBOV in the future. In a typical vaccine or drug study, surviving NHPs are euthanized at the end of the experiment (typically 28 days after infection), once they are shown to be clear of viremia and without virus shedding on at least 2 separate sample dates. Interestingly, the absence of detectable virus by PCR in 2 samples collected on 2 different dates is also one of the major release criteria for convalescent patients (another being the absence of observable symptoms). These developments suggest that, in addition to blood tests, further examination could be performed, for example in breast milk, semen, vaginal secretions, urine, ocular, and cerebrospinal fluids, to follow the evolution of virus clearance

with more precision [14]. This could enhance information about the possibility of reoccurrence of disease and/or transmission. Furthermore, optimal vaccination regimens resulting in robust immune responses, as well as prompt administration of therapies, could be critical to minimize EBOV dissemination to multiple organs. Therefore, the mechanism of how EBOV is able to bypass barriers to privileged sites and invade the brain, testis, and ocular fluid, and whether this phenomenon also occurs with other filovirus species such as Sudan, Bundibugyo or Marburg viruses, should be a focus for future research to aid in the management of cases and outbreaks.

Notes

Acknowledgments. We thank Dr Tom Geisbert for providing unpublished animal data that was described in this article.

Financial support. This work was supported by the Public Health Agency of Canada, the Canadian Safety and Security Program (grant to X. Q. and G. K.), the Canadian Institutes of Health Research (Banting Postdoctoral Fellowship to G. W.), and the Chinese Academy of Sciences (President's International Fellowship Initiative support to G. W.).

Potential conflicts of interest. All authors: No reported conflicts. All authors have submitted the ICMJE Form for Disclosure of Potential Conflicts of Interest. Conflicts that the editors consider relevant to the content of the manuscript have been disclosed.

References

- World Health Organization. Ebola situation report—7 October 2015. <http://apps.who.int/ebola/current-situation/ebola-situation-report-7-october-2015>. Accessed 9 October 2015.
- World Health Organization. Ebola vaccines, therapies, and diagnostics. http://www.who.int/medicines/emp Ebola_q_as/en/. Accessed 16 October 2015.
- ProMED-mail. Ebola update (116): WHO, Scottish nurse relapse, suspected, research, funding. <http://www.promedmail.org/direct.php?id=3708317>. Accessed 12 October 2015.
- CIDRAP. Neuro complications cited in UK nurse's Ebola case. <http://www.cidrap.umn.edu/news-perspective/2015/10/neuro-complications-cited-uk-nurses-ebola-case>. Accessed 16 October 2015.
- Martines RB, Ng DL, Greer PW, Rollin PE, Zaki SR. Tissue and cellular tropism, pathology and pathogenesis of Ebola and Marburg viruses. *J Pathol* **2015**; 235:153–74.
- Bausch DG, Towner JS, Dowell SF, et al. Assessment of the risk of Ebola virus transmission from bodily fluids and fomites. *J Infect Dis* **2007**; 196(suppl 2):S142–7.
- Deen GF, Knust B, Broutet N, et al. Ebola RNA persistence in semen of Ebola virus disease survivors - preliminary report. *N Engl J Med* **2015**; doi:10.1056/NEJMoa1511410.
- Varkey JB, Shantha JG, Crozier I, et al. Persistence of Ebola virus in ocular fluid during convalescence. *N Engl J Med* **2015**; 372:2423–7.
- Edwards JK, Kleine C, Munster V, et al. Interpretation of negative molecular test results in patients with suspected or confirmed Ebola virus disease: report of two cases. *Open Forum Infect Dis* **2015**; 2:1–4.
- Centers for Disease Control and Prevention. Ebola virus disease complicated by late-onset encephalitis and polyarthrits, Sierra Leone. http://wwwnc.cdc.gov/eid/article/22/1/15-1212_article. Accessed 15 June 2016.
- Mate SE, Kugelmann JR, Nyenswah TG, et al. Molecular evidence of sexual transmission of Ebola virus. *N Engl J Med* **2015**; 373:2448–54.
- Qiu X, Wong G, Fernando L, et al. mAbs and Ad-vectored IFN- α therapy rescue Ebola-infected nonhuman primates when administered after the detection of viremia and symptoms. *Sci Transl Med* **2013**; 5:207ra143.
- Larsen T, Stevens EL, Davis KJ, et al. Pathologic findings associated with delayed death in nonhuman primates experimentally infected with Zaire Ebola virus. *J Infect Dis* **2007**; 196(suppl 2):S323–8.
- Bevilacqua N, Nicastrì E, Chinello P, et al. Criteria for discharge of patients with Ebola virus diseases in high-income countries. *Lancet Glob Health* **2015**; 3:e739–40.